



PRESENTING CLINICAL SIGNS

DATE History: Grade 4/6 murmur. Asymptomatic.

12/28/22 ECHOCARDIOGRAPHIC FINDINGS

2D, M-mode, and Doppler study.

PERFORMED BY: There is mild to moderate left atrial dilation. The mitral valve leaflets are thickened and exhibit systolic prolapse. A moderate jet of eccentric mitral regurgitation is present. There is mild to moderate left ventricular dilation. Left ventricular systolic function is hyperdynamic. The aorta and aortic valve are normal. Right atrial and right ventricular dimensions are normal. The tricuspid valve appears normal, though trace tricuspid regurgitation is present. The pulmonary artery and pulmonic valve are normal. No shunting lesions are visualized. No heartworms are visualized. No pericardial effusion or cardiac masses are seen.

Kelly Vazquez

INTERPRETED BY

Keith Blass, DVM,
MS, DACVIM
(Cardiology)

LA - 31.9 mm
LVIDd - 31.1 mm
LVIDs - 14.0 mm
FS - 55%
RA - 16.5 mm
LVOT - 1.47 m/s
RVOT - 1.13 m/s

PATIENT

Paco Seymour

SPECIES ASSESSMENT/RECOMMENDATIONS

Degenerative mitral valve disease

Canine

This examination demonstrates moderate regurgitation of blood across Paco's mitral valve resulting from degenerative valve disease. Secondary to his regurgitation, Paco has mild to moderate dilation of both his left atrium and left ventricle, though his left ventricular systolic function is well-preserved. Paco's mitral valve disease is still compensated, however, he is at risk for the development of clinical signs secondary to it, such as coughing, exercise intolerance, syncope, and labored breathing, therefore, careful monitoring for these is recommended.

BREED

Maltese Mix

SEX

I recommend starting Paco on pimobendan (1.25 mg BID), as this medication should help to slow the progression of his mitral valve disease.

MN

A recheck echocardiogram is recommended in 9 months. Thoracic radiographs are recommended if Paco experiences respiratory clinical signs.

AGE

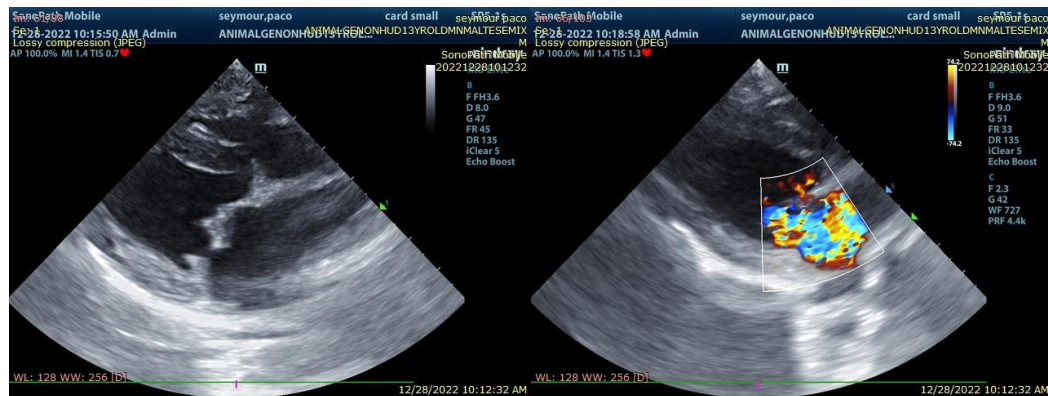
13 y

WEIGHT

12.7 lb

HOSPITAL NAME

Animal General on Hudson



REFERRING VET

Dr. Tierney

The information and recommendations provided are based on the images presented by the



DATE referring veterinarian. No evaluation can be communicated regarding pathology that was not visible in the image/video clips provided.

12/28/22 Thank you for this referral. If the clinical or image interpretation does not parallel your findings or if I can be of any further assistance please contact me.

PERFORMED BY: Keith Blass, DVM, MS, DACVIM (Cardiology)
Kelly Vazquez KeithBlass@gmail.com
631-804-5754

INTERPRETED BY

Keith Blass, DVM,
MS, DACVIM
(Cardiology)

PATIENT

Paco Seymour

SPECIES

Canine

BREED

Maltese Mix

SEX

MN

AGE

13 y

WEIGHT

12.7 lb

HOSPITAL NAME

Animal General on
Hudson

REFERRING VET

Dr. Tierney